

Nail Regeneration by Elongation of the Partially Destroyed Nail Bed

Gottfried Lemperle, M.D., Ph.D., Martin Schwarz, M.D., and Stefan M. Lemperle, M.D.

San Diego, Calif.; and Freiburg im Breisgau, Germany

Patients with partially destroyed fingernails tend to hide them, and such patients often do not find help because fingernails are considered of little functional value. To improve the aesthetic appearance of such nails, a simple excision of the destroyed nail matrix can stimulate the growth of the residual healthy matrix and regenerate the nail. Prerequisite is a healthy nail residue of at least the lunula. An excision of an en bloc, crescent-shaped, full-thickness scar, 5 mm at its greatest width and extending from one lateral nail fold to the other, increases the length of the nail plate. Together with the matrix, the nail will grow about 4 mm distally. A second crescent-shaped excision 1 to 2 months later will further lengthen the nail until it has gained full length. Normal nail growth was achieved in 11 patients who had partially scarred nail beds after mycosis or trauma. (*Plast. Reconstr. Surg.* 111: 167, 2003.)

Fingernails can be lost or grow short after mycotic infections, third-degree burn injury, traumatic destruction, chronic or psoriatic eczema, surgical excision of subungual tumors and warts, self-infliction, or after long-lasting subungual hematomas.¹ Often the residual nail growth is thickened, discolored, or split.² Antimycotic treatment is rather difficult because the fungi hide beneath the distorted toenail or fingernail. In our experience, the optimal treatment for mycotic nails is the excision of only the lifted-off part of the nail as far proximally as possible and subsequent antimycotic therapy under an occlusion bandage for at least 4 weeks. During this time, the residual nail grows from a now-healthy nail bed at 0.1 mm per day in the toes and 0.2 mm in the fingers.

A missing fingernail is more a psychological

than a functional problem. Women especially file or cut their fingernails at least once a week, and they try to camouflage ugly and uneven looking nails. Unfortunately, painting an atrophied nail bed does not improve its appearance, and artificial nails cannot be glued to it. Different kinds of fixation devices, such as the creation of a snap-fastener in the nail bed, are only temporarily stable.^{3,4}

In the past, many attempts have been made to reconstruct destroyed nail beds surgically.⁵⁻¹⁵ If the total loss of a fingernail is so disturbing to the patient that she or he desires reconstruction, the safest option is the microsurgical transfer of the entire nail bed from the great toe to the thumb^{8,14} or half a great toe nail bed to a long finger.¹² If the distal bony phalanx is shortened as well, a partial transfer of a toe phalanx is recommended.^{11,15} In 1988, free grafting of a nail bed on decorticated bone was declared the method of choice.⁷ This approach causes little morbidity at the donor site, but it often results in unpredictable growth of the nail.²

The longtime reluctance toward free nail bed grafting originates from a report in 1955⁵ that describes nail growth in 10 of 25 free grafts, with only 20 percent of the grafts yielding a cosmetically acceptable result. Finally in 1997, Endo et al.¹⁰ demonstrated complete and aesthetically pleasing nail growth after microsurgical transfer of a full-thickness nail bed graft from the toe to the distal phalanx of a finger. Brown et al.¹³ and Foucher et al.¹⁴ published similar good results in 1999. Therefore,

From the Division of Plastic Surgery, University of California, San Diego, and the Center for Ambulatory Diagnostics and Surgery. Received for publication December 11, 2001; revised February 28, 2002.

Presented at the Symposium on Hand Surgery, in Hannover, Germany, October 20, 1999.

DOI: 10.1097/01.PRS.0000037760.20344.14

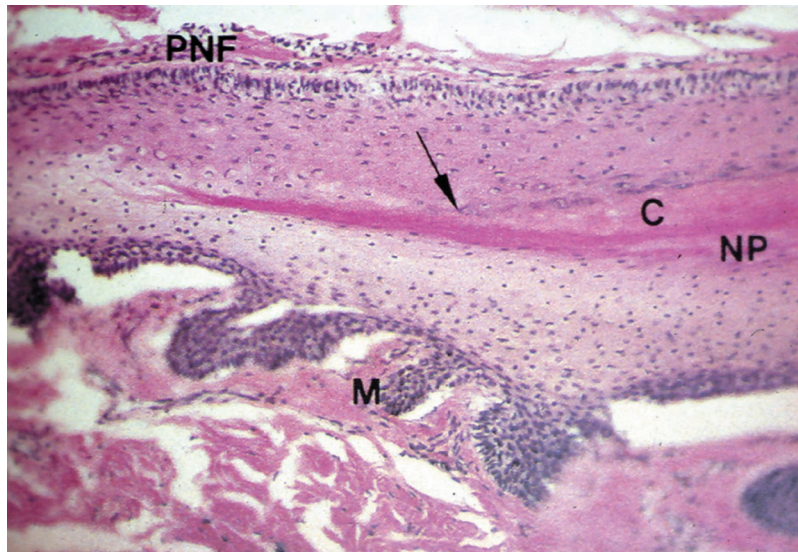


FIG. 1. Histological section of the root of a nail. *PNF*, proximal nail fold; *arrow*, keratin deposition; *C*, cuticle; *NP*, nail plate; *M*, matrix.

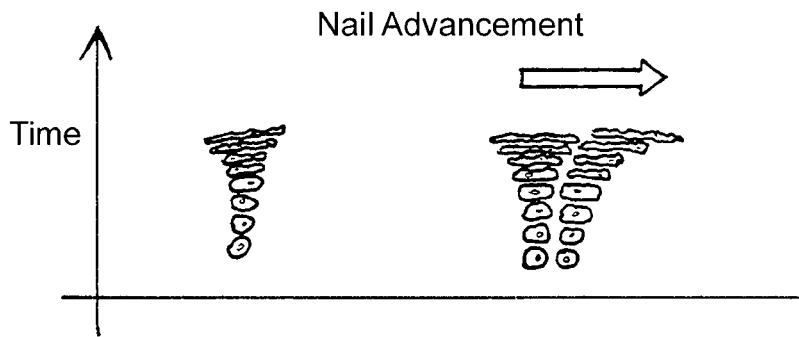


FIG. 2. Growth kinetics of the nail matrix.

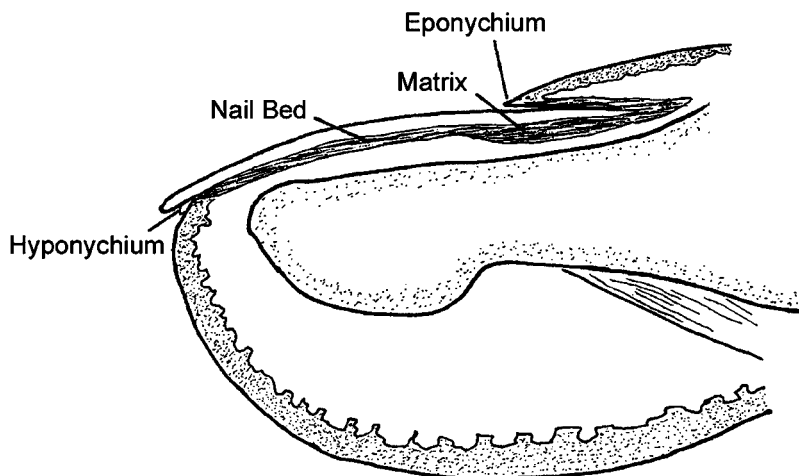


FIG. 3. Anatomy of the nail.

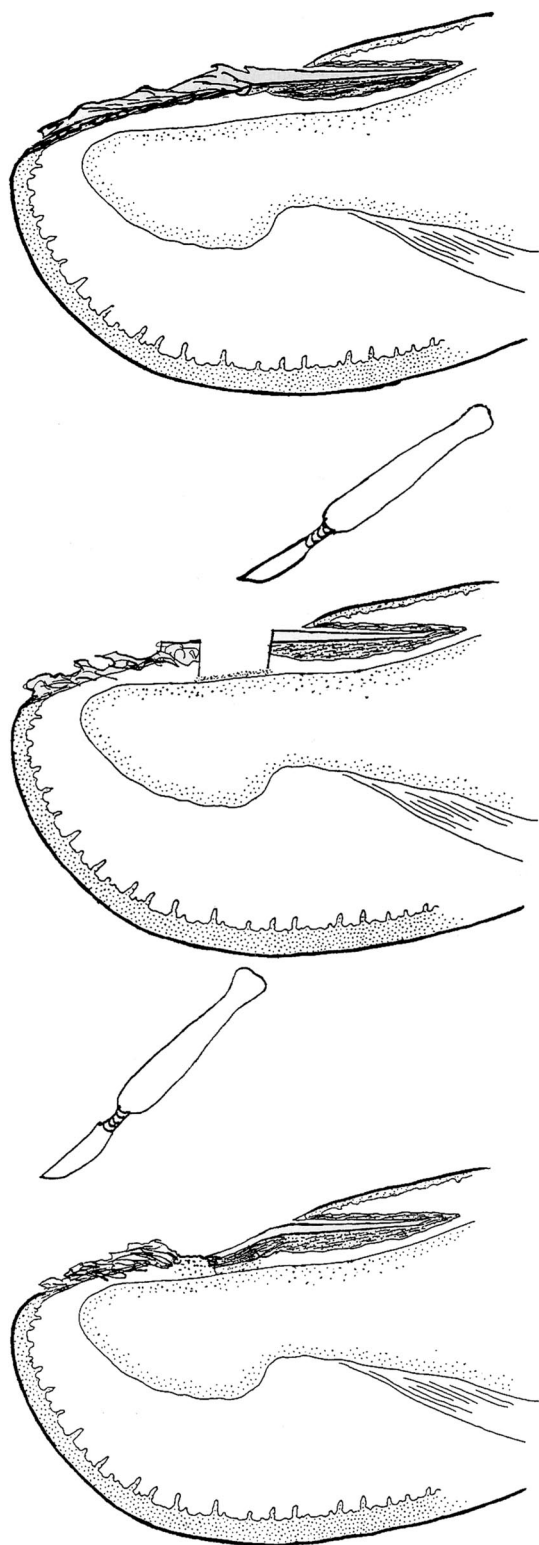


FIG. 4. (Above) Scarred nail bed with intact lunula. (Center) En bloc, crescent-shaped excision of the scar down to the periosteum of the intact lunula distally. (Below) Partial regeneration of the created defect. The proximal 75 percent of the nail is covered by new matrix and nail, and the distal 25 percent is covered by new scar tissue. The latter and an additional 4 mm can be excised 3 to 4 weeks later.

the free full-thickness graft of a nail bed¹⁵ may be considered the method of choice in the reconstruction of a total missing nail bed.

PHYSIOLOGY OF NAIL GROWTH

In general, growing and dividing tissue cells grow multidirectionally. The nail bed, however, forces the nail to grow in one direction (Fig. 1). During maturation of the nail, the nail-forming cells of the matrix become successively flatter and wider and need more space (Fig. 2). A cube that could accommodate 10×10 keratinocytes could host only 2×2 mature nail keratinocytes.¹⁶

The special parabolic shape at the root of the nail and the above-described need for space are the keys to understanding nail growth. Like a parabolic mirror, the nail folds guide all growing cells into one direction (Fig. 3).¹⁷⁻¹⁹ Figure 4 clearly illustrates what happens after an injury to the nail fold. A minor injury or third-degree burn to the nail fold leads to a disruption of the vector forces and, therefore, to nail growth in different directions. The clinical appearance shows a depression and, later, a horizontal ridge in the nail that will persist as long as the nail fold is not reconstructed by one or two transposition flaps.²⁰

PATIENTS AND METHODS

Technique of Serial Excisions

If there is still a residue of the nail bed with some nail growth in the region of the lunula (Fig. 4, above), serial excisions can be applied to elongate this nail. After a finger block with local anesthesia, with or without adrenaline²¹ and additional local infiltration, a 5-mm-wide crescent-shaped stripe of scarred nail bed directly adjacent to the healthy nail is excised down to the periosteum of the distal phalanx (Fig. 4, center). After a few minutes of lifting up the hand or foot and compression of the wound, the bleeding will stop. An antibiotic or antimycotic ointment and a bandage are applied for 3 to 4 days. Thereafter, a simple Band-Aid is sufficient to cover the defect for another 2 weeks until full epithelization of the nail bed is achieved (Fig. 4, below). During this time, approximately 75 percent of the wound will be closed from the proximal wound margin and 25 percent from the distal scarred margin. During this time, the nail will grow from its advancing matrix.

After regeneration of the new nail bed and

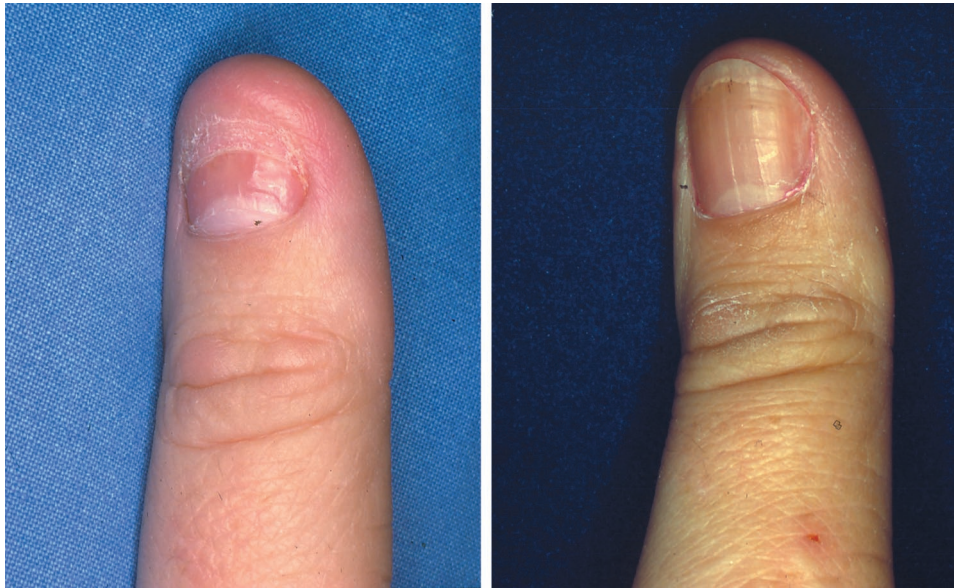


FIG. 5. (*Left*) Postmycotic nail atrophy. Five weeks previously, a 5-mm-wide, crescent-shape excision was performed. The second excision will be distal to the new nail. (*Right*) Normal nail growth 3 months after the last of two crescent-shaped excisions.

nail over 2 to 3 months, a second crescent-shaped excision of the remaining scar tissue is performed. If the nail has not completely regenerated after another 2 months, a third scar excision can be added until the nail looks perfect (Fig. 5).

RESULTS

Between 1990 and 1994, a total of 11 partially destroyed nail beds were reconstructed according to the described method. Six were caused by mycosis (Fig. 5) and five by trauma (Figs. 6 and 7). There was no failure or complication. Complications after nail surgery have been described²² because the majority of postoperative nail deformities result from nail matrix damage.

DISCUSSION

Fingernails have little functional importance and are mainly used for scratching. If they are lost after injury, burn, or radiation,²³ however, at least one on a thumb and one on a long finger will be of great value in picking up small objects²⁴ and pushing buttons through button holes. However, professional guitar players compensate for the loss of a fingernail with the development of a callus at the pulp. Of course, fingernails contribute to tactile sensitivity and to the stability of the fingertip.

Knowing the growth kinetics of a nail, the

described technique takes advantage of the healthy remains of the nail bed and its vectors to stimulate nail regeneration. The excision of a scarred strip of nail bed stimulates the matrix cells of the proximal healthy nail bed to grow unidirectionally and much faster than the distal wound margin, with its multidirectionally growing immature granulation tissue. Therefore, the described method could also be used effectively in the treatment of other nail deformities, such as hook nails²⁵ and pincer nails.²⁶ The pincer nail forms a tube until it pinches the nail bed.

The common treatment of painful pincer nails is still nail bed ablation and healing by secondary intention or skin grafting. Many surgeons²⁷ today will use Zook's method,²⁸ which includes removing the nail, freeing the lateral perionychial attachments to the bone, and flattening the nail matrix by elevating its lateral portions with two underlying dermal grafts. The results are excellent.

Because the lunula is flat in most cases of pincer nails, the presented method might be a simple alternative to Zook's sophisticated approach. First, a crescent-shaped piece of 5 mm in length from a tubed pincer nail is cut out on the level of the lunular border down to the periosteum and secondary healing is induced. After the gap has been closed, the second crescent piece is removed and, eventually, the

third, thereby rogueing off the dorsal tuft if it is abnormally pronounced.

Of all the described methods of nail reconstruction, only the eponychial flap of Bak-hach¹² seems actually to elongate the nail matrix. The described technique of serial excisions can be used effectively in all partially destroyed or deformed nail beds after trauma, mycosis, tumor removal, and some genetic malformations.

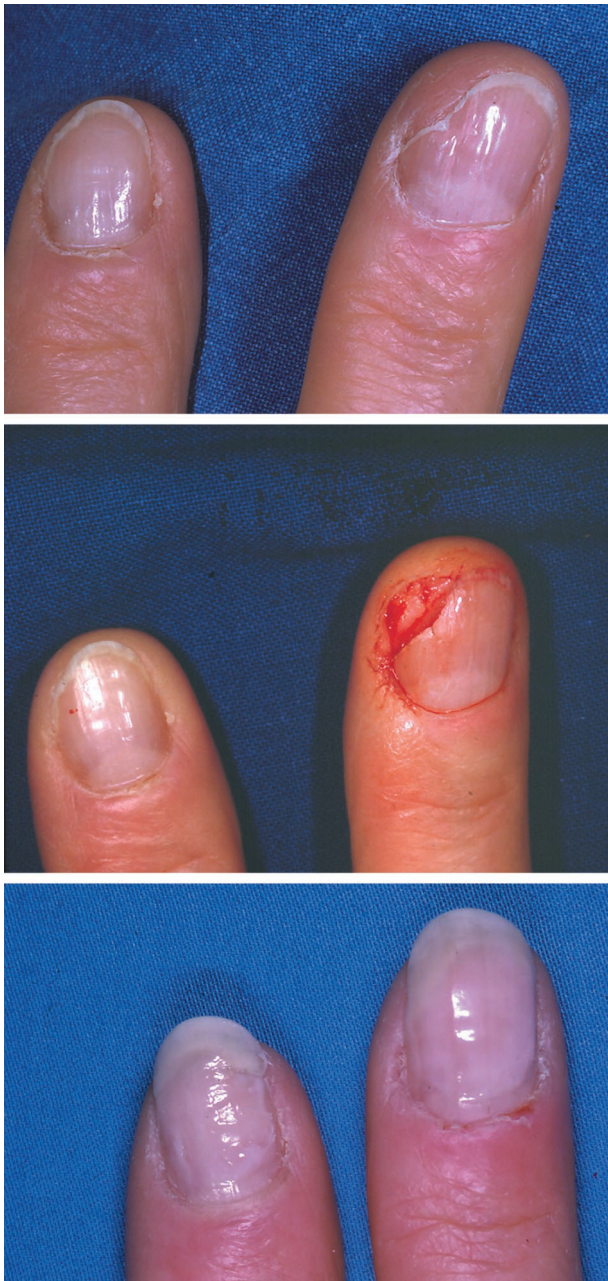

FIG. 6. (Above) Partial fingernail defect after trauma. (Center) Excision of the scarred nail bed. (Below) Six weeks after excision and secondary wound healing.

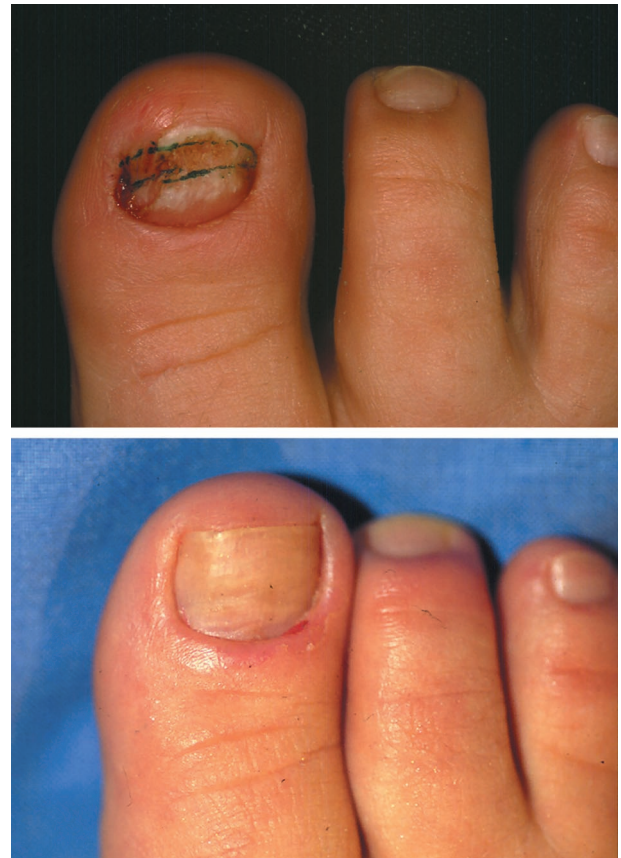

FIG. 7. (Above) Partial defect after trauma to the great toe. The crescent-shaped excision is outlined. (Below) Normal nail growth 2 years after one excision.

Gottfried Lemperle, M.D., Ph.D.
 Division of Plastic Surgery
 University of California, San Diego
 302 Prospect Street #1
 La Jolla, Calif. 92037
 glemperle@aol.com

REFERENCES

1. Baran, G. Common-sense advice for the treatment of selected nail disorders. *J. Eur. Acad. Dermatol.* 15: 97, 2001.
2. Ashbell, T., Kleinert, H., Putcha, S., and Kutz, J. The deformed fingernail. *J. Trauma* 7: 177, 1967.
3. Krull, E. A., Zook, E. G., Baran, R., and Haneke, E. *Nail Surgery: A Text and Atlas*. Philadelphia: Lippincott Williams & Wilkins, 2001.
4. Beasley, R. W., and de Breze, G. M. Prosthetic substitution for fingernails. *Hand Clin.* 6: 105, 1990.
5. McCash, C. R. Free nail grafting. *Br. J. Plast. Surg.* 8: 19, 1955.
6. Foerstner, H. Nagelbett-Transplantation, eine Möglichkeit der Rekonstruktion. *Akt. Traumatol.* 16: 34, 1986.
7. Matsuba, H. M., and Spear, S. L. Delayed primary reconstruction of subtotal nail bed loss using split-thickness nail bed graft on decorticated bone. *Plast. Reconstr. Surg.* 81: 440, 1988.

8. Endo, T., and Nakayama, Y. Short pedicle vascularized nail flap. *Plast. Reconstr. Surg.* 97: 656, 1996.
9. Hirase, Y., Kojima, T., and Matsui, M. Aesthetic fingertip reconstruction with a free vascularized nail graft: A review of 60 flaps involving partial toe transfer. *Plast. Reconstr. Surg.* 99: 774, 1997.
10. Endo, T., Nakayama, Y., and Soeda, S. Nail transfer: Evolution of the reconstructive procedure. *Plast. Reconstr. Surg.* 100: 907, 1997.
11. Woo, S. H., and Seul, J. H. Distal thumb reconstruction with a great toe partial-nail preserving transfer technique. *Plast. Reconstr. Surg.* 101: 114, 1998.
12. Bakhach, J. Lambeau eponychial. *Ann. Chir. Plast. Esthet.* 43: 259, 1998.
13. Brown, R. E., Zook, E. G., and Russell, R. C. Fingertip reconstruction with flaps and nail bed grafts. *J. Hand Surg. (Am.)* 24: 345, 1999.
14. Foucher, G., Nagel, D., and Briand, E. Microvascular great toenail transfer after conventional thumb reconstruction. *Plast. Reconstr. Surg.* 103: 570, 1999.
15. Koshima, I., Itoh, S., Takahashi, Y., Nanba, Y., and Kishimoto, K. Free vascularized nail graft under digital block. *J. Reconstr. Microsurg.* 17: 599, 2001.
16. Kligman, A. Why do nails grow out instead of up? *Arch. Dermatol.* 84: 313, 1968.
17. Fleckman, P., and Allan, C. Surgical anatomy of the nail unit. *Dermatol. Surg.* 27: 257, 2001.
18. Zaiac, M. N., and Weiss, E. Mohs micrographic surgery of the nail unit and squamous cell carcinoma. *Dermatol. Surg.* 27: 346, 2001.
19. Achten, G. Histopathology of the nail. In M. Pierre (Ed.), *The Nail*. Edinburgh: Churchill-Livingston, 1987. P. 12.
20. Schwarz, M., Lemperle, G., and Hasse, F. Rekonstruktion des Nagelbettes durch Serienexzision. *Akt. Chir.* 27: 252, 1992.
21. Denkler, K. A comprehensive review of epinephrine in the finger: To do or not to do. *Plast. Reconstr. Surg.* 108: 114, 2001.
22. Moossavi, M., and Scher, R. K. Complications of nail surgery: A review of the literature. *Dermatol. Surg.* 27: 225, 2001.
23. Krizek, T. J., and Ariyan, S. Severe acute radiation injuries of the hand. *Plast. Reconstr. Surg.* 51: 14, 1973.
24. Smith, S. M. Subjective experiences during a 32-year period after resurfacing of hands for severe and acute radiation burns. *Plast. Reconstr. Surg.* 51: 23, 1973.
25. Buback, P. J., Richey, M. D., and Engrav, L. H. Hook nail deformity repaired using a composite toe graft. *Plast. Reconstr. Surg.* 90: 1079, 1992.
26. Baran, R., Haneke, E., and Richert, B. Pincer nails: Definition and surgical treatment. *Dermatol. Surg.* 27: 261, 2001.
27. Suzuki, K., Yagi, I., and Kondo, M. Surgical treatment of pincer nail syndrome. *Plast. Reconstr. Surg.* 63: 570, 1979.
28. Brown, R. E., Zook, E. G., and Williams, J. Correction of pincer-nail deformity using dermal grafting. *Plast. Reconstr. Surg.* 105: 1658, 2000.